

FEATURE ARTICLES

Functional Rating for Knee Arthroplasty: Comparison of Three Scoring Systems

*Raymond Y.L. Liow, FRCS(Tr&Orth); Karen Walker, RGN;
Mohammad A. Wajid, FRCSEd(Orth); Gurinder Bedi, FRCS;
Catherine M.E. Lennox, FRCSEd(Orth)*

Decreased Range of Motion Following Acute Versus Chronic Anterior Cruciate Ligament Reconstruction

*William I. Sterett, MD; Kirk S. Hutton, MD; Karen K. Briggs, BS, MBA;
J. Richard Steadman, MD*

Refracture Following Plate Removal in Supracondylar-Intercondylar Femur Fractures

Brian L. Davison, MD

Idiopathic Osteoarthritis of the Hip: Incidence, Classification, and Natural History of 272 cases

George Hartofilakidis, MD; Theophilos Karachalios, MD

EDITORIAL:

The Health of Our Profession

Robert D'Ambrosia, MD; Jennifer A. Kilpatrick, BA, ELS

TIPS & TECHNIQUES:

Suture V Technique: A Method for Supplementing Soft-Tissue Interference Fixation of Anterior Cruciate Ligament Grafts

Joseph Bernstein, MD, MS; Virak Tan, MD

BRIEF REPORT:

Overdiagnosed Sciatica and Stenosis, Underdiagnosed Hip Arthritis

Robert L. Swezey, MD

TRAUMA UPDATE: Intramedullary Nailing of Distal Tibial Fractures: A Technique to Prevent Malalignment

George V. Russell, Jr, MD; Albert W. Pearsall IV, MD

REVIEW:

The Treatment of Chronic Scapholunate Dissociation: An Evidence-Based Assessment of the Literature

*Heidi Taylor Bloom, MD; Alan E. Freeland, MD;
Vaughan Bowen, MD, FRCS(C), MB, ChB; Linda Mrkonjic, MD, FRCS(C)*

This continuing medical education activity is sponsored by SLACK Incorporated.

CME

The Role of Measured Resistance Exercises in Adolescent Scoliosis

Vert Mooney, MD
Allison Brigham, BS

Abstract

Twenty adolescent patients (18 girls and 2 boys) with scoliosis ranging from 15°-41° in their major curve were treated with a progressive resistive training program for torso rotation. All patients demonstrated an asymmetry of rotation strength measured on specialized equip-

ment, and surface electrode electromyograms showed inhibition of lumbar paraspinal muscles. Sixteen of 20 patients demonstrated curve reduction, and no patient showed an increase in curve.

According to Lowe et al,¹ the cause of idiopathic scoliosis continues to elude investigators. The consensus is that the etiology is multifactorial. It is difficult to separate cause and effect. For instance, the various studies that showed deficient proprioception, such as abnormal sway² and deficient proprioception in scoliosis patients compared to normal patients,³ suggest these conditions are secondary to the deformity and do not lead to a basic neurologic deficit.

One factor that is relative for causation and treatment is the evidence of muscle asymmetry associated with the curvature. Histochemical and histologic studies demonstrate a difference in muscle status on the convex versus the concave side.⁴⁻⁸ Also, asymmetric myoelectric activity on the convex versus concave side has been noted.⁹⁻¹³ Hyperactivity seems to occur on the

convex side. Muscle mass, as identified by real-time ultrasound, has shown asymmetry as well.¹⁴ In this study, the lumbar multifidus muscles were larger on the opposite side of the thoracic convexity and on the concave side of the thoracolumbar curves.¹⁴

No data exists concerning strength differentials between sides for adolescents with scoliosis. A study that evaluated trunk extensor strength isometrically in a sagittal range did not compare one side to the other.¹⁰ Extensor strength was normal in patients with scoliosis.

No study documents the benefits of exercise in the treatment of scoliosis. One preliminary study investigated the effects of an exercise program on adolescents with minimal idiopathic scoliosis.¹⁵ The program was comprised of a series of calisthenics that included sit-ups, leg lifts, and pelvic tilts; no specific training to the spine was included. No particular rationale for treatment was offered, and no significant difference in curvature was found between the exercise and control groups. Strenuous exercise at 20 repetitions was not moni-

tored. The authors noted that most patients did not exercise according to instructions. Only 59% remembered the exercises. No strength measurements were made at baseline or follow-up. No specific measurement of compliance was documented.

Asymmetry should offer some benefit to strength training. Evidence exists that asymmetric strength can create scoliosis. A Scandinavian study found that among elite athletes with single arm skills, such as javelin throwers and tennis players, a small thoracic curve of approximately 10° develops in >80% of participants who developed their skills during adolescence.¹⁶ In a Bulgarian study of 100 girls engaged in rhythmic gymnastics, 12% had scoliotic curves of ≥10°.¹⁷

Asymmetric strength also is demonstrated in junior olympic swimmers.¹⁸ In a study of 336 swimmers who were evaluated for scoliosis, 16% had mild curves, all with the convex curvature on the hand dominant side of the body.¹⁸ Again, this suggests that muscle imbalance is a possible cause of scoliosis. Asymmetric tor-

From US Spine & Sport Center, San Diego, Calif.

Reprint requests: Vert Mooney, MD, US Spine & Sport, 3444 Kearny Villa Rd, Ste 205, San Diego, CA 92123.

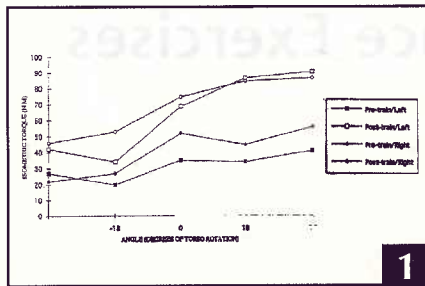


Figure 1: Pre- and post-training strength curves on the computerized MedX torso rotation machine (MedX 96 Inc, Ocala, Fla).

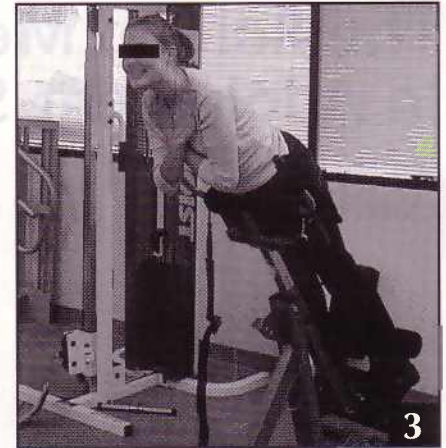
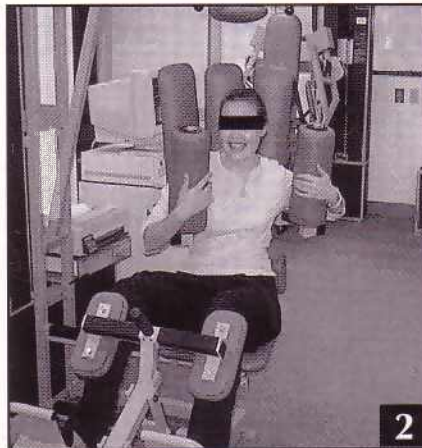


Figure 2: MedX exercise only torso rotation unit (MedX 96 Inc, Ocala, Fla). Figure 3: BackStrong variable angle roman chair (Backstrong, Brea, Calif).

sion seems to be a factor. Therefore, torsional strength should be compared between sides.

All studies related to exercise and scoliosis comment on repetition, but not performance. As a therapy, exercise needs to be measured. Also, if it is to be effective, compliance must be consistent and monitored, and progress should be evaluated.

A prospective study measuring torso rotation strength with a specific tool and the effect of resisted exercises on the strength was performed and reported in a preliminary study.¹⁹ This article reports the continued efficacy with less complex equipment on additional patients.

MATERIALS AND METHODS

The computerized MedX rotary torso machine (MedX 96 Inc, Ocala, Fla) with torso rotation strength training and measurement of torso rotation range was used. With this device, the pelvis is stabilized in a sitting position, but the torso is free to move in a 96° arc, rotating from left to right or vice versa.

To allow standardized evaluation for this study, torso rotation was restricted to 36° in each direction. Thus, the full torso rotation was 72°. This device also stops every 18° to measure isometric strength. Therefore, for the full 72° arc rotating from 36° on the left to 36° on the right, isometric strength is measured at five points.

Rotation is resisted in the exercise mode by a weight stack with resistance translated from the rotary axis by a cam,

therefore, constant resistance is present through full arc of rotation. In this exercise mode, the amount of resistance is known based on the weight stack and the number of repetitions accomplished before fatigue is recorded. Typically in this exercise mode, 20 repetitions at one level of resistance are accomplished before the resistance is increased by approximately 5% at the next exercise session. Based on this study, two sessions per week with MedX lumbar extension equipment showed sufficient improvement (Figure 1).^{20,21}

Testing on the MedX machine was performed at monthly intervals. The isometric pattern was displayed from end rotation to beginning rotation. It was strongest at the beginning of rotation.

In the initial study, myoelectric activity of the muscles also was monitored. Surface electromyographs were recorded (ME1000; Mega Electronics, Kuopo, Finland). The multifidus muscle was monitored posteriorly and the oblique muscles were monitored anteriorly. The electrodes were placed 3 inches below the cage and 4 inches from the midline on each side.

For the expanded study, a noncomputerized rotary torso machine (MedX) was used. This device was considerably less expensive and allowed the patient to place him- or herself into the device independent of an attendant. The resis-

tance was monitored by the weight stack, similar to the computerized rotary equipment. Torso rotation is resistive in the same manner with the pelvis restrained and rotation range variable (Figure 2).

The first study was comprised of 12 patients, and 8 additional patients were added to the follow-up study. The participants agreed to a 4-month training program. Based on the findings of the initial study, an additional treatment program was added. All patients in the second phase also were treated on a variable angle roman chair (BackStrong, Brea, Calif) to challenge their lumbar extensors (Figure 3). This device allowed increasing angulation for increasing challenge to the extensor musculature.

A total of 20 patients (18 girls and 2 boys) with scoliosis ranging from 15°-41° in the major curve, were treated with a progressive resistive training program for torso rotation. Treatment was twice a week until skeletal maturity or documented curve reduction was noted. No patient was braced during treatment. Starting resistance was one-third of body weight. Equal resistance was used in left and right rotation, although initially rotation was weaker in one direction compared to the other. Once the patient was able to complete 20 repetitions, the resistance was increased by 5%. Rotation range was increased as tolerated.

RESULTS

The initial study found that the isometric strength differential between sides ranged from 12%-47%. In 10 of 12 patients, muscles were weaker on the concave thoracic curve. The remaining 2 patients had double curves with the weak side on the concavity of the lumbar spine and thus on the convex thoracic spine. No correlation was noted between the discrepancy of strength differences and severity of the curves.

Ten staff members were tested on the torso rotation machine (5 men and 5 women; average age: 26 years). None were elite athletes using unilateral arm function, and none had scoliosis. Rotation was equal to either side using the computerized torso rotation machine. Results of electromyographic studies paralleled strength differences, and myoelectric activity was consistently asymmetric at onset of training. Asymmetry occurred between lumbar paraspinal muscle sides and between the abdominal obliques. At the conclusion of physical training, however, myoelectric activity was equal (Figure 4).

In that study, one patient with a 60° curve was placed on the program, but continued to progress. She eventually underwent corrective surgery. Based on this, we decided not to include patients with curvatures >45°. Patients in the combined studies are listed in the Table.

Sixteen of 20 patients demonstrated curve reduction, and although some fluctuation occurred, none of the remaining 4 patients had a persistent increase in curve. The pretraining average curvature was 28.2°±13.2°. Post-training curvature was 23°±14.1°. The percentage improvement was 20%±23%, and in the new study, a 132.5%±61.4% increase in dynamic strength was noted. No patient required surgery or bracing.

DISCUSSION

An important finding from these studies was the asymmetry of torso rotation strength in adolescent patients with scoliosis. This deficiency in strength is reflected by apparent muscle inhibition of the paraspinal muscles. These studies

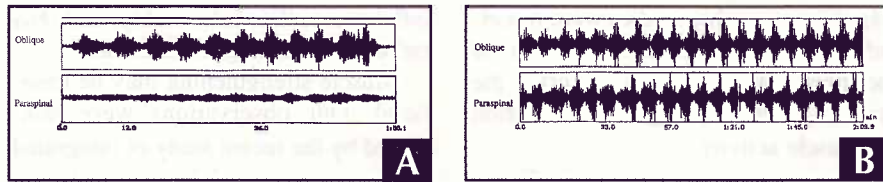


Figure 4: Electromyographs during dynamic torso rotation exercise at the beginning (A) and end (B) of the study.

TABLE
Patient Demographics

Patient Age (y)	Curve Type	Dominant Hand	Pretraining Curve (°)	Post-training Curve (°)
11	Left thoracic	Right	25	5
13	Right thoracic	Right	30	28
14	Right thoracic	Right	45	32
13	Right thoracic lumbar	Right	41	38
11	Left thoracic	Left	20	19
12	Right thoracic	Right	31	16
12	Right thoracic	Right	29	20
14	Left thoracic lumbar	Right	20	20
15	Right thoracic	Right	22	21
16	Right thoracic lumbar	Right	60	67
12	Left thoracic	Left	29	28
14	Right thoracic	Right	50	32
16	Right lumbar	Right	35	35
13	Right lumbar	Right	14	10
16	Left thoracic	Left	11	11
13	Left lumbar	Right	15	15
14	Right thoracic	Right	10	4
12	Right thoracic	Right	23	18
17	Right thoracic	Right	34	25
14	Right thoracic lumbar	Right	20	15

also show that this muscle deficiency can be corrected with specific torso rotation and lumbar extensor strengthening. This is associated with improvement in curvature in most patients.

Failure of past exercise training to show effective improvement for adolescent idiopathic scoliosis may be ascribed to many factors. The earlier study incorporated specific equipment to measure the exercise. A specific rationale existed for the exercise program, ie, unequal rotational strength. In the past, without a specific piece of equipment, it was not possible to note initial strength differentials, compliance, or a change in strength.

As shown in the study by Stone et al,¹⁵ exercise program compliance by otherwise pain-free adolescents is a considerable problem. In our study, because there was minimal demand on

time and objective feedback of improving performance, compliance was not a problem. None of the participants dropped out of this study.

In the past, in an effort to substitute for volitional exercise compliance but achieve specific muscle strengthening, electrical muscle stimulation was tried. Using surface electrodes, early clinical results were encouraging.^{22,23} Axelgaard et al²⁴ reported the correction of spinal curvature in animal studies and clinical practice. However, when this was applied to a broad group of adolescent patients with scoliosis, it was found to be ineffective.²⁵ In this study of 25 patients with curvatures between 25° and 35°, 1 improved and 10 became worse. It should be noted that in the literature that discuss electrical stimulation, no before and after strength testing or any comparative

electromyographic studies were reported. Surface electrode stimulation of peripheral muscles does not bring the central nervous system into facilitation of muscle activity.

In a recent meta-analysis of efficacy of nonoperative treatments for idiopathic scoliosis, electrical stimulation was disregarded¹ and exercise was not mentioned. The only nonoperative care with a consensus is bracing. However, with bracing, clinicians are aware that efficacy is not universal. In a series of 1020 patients who wore braces for significant scoliosis, Lonstein and Winter²⁶ found a lack of significant progression in 78% of patients. However, longer bracing, beginning with the curve at 25°, is recommended to gain that level of improvement. Noonan et al²⁷ believed that bracing did not significantly change the natural history in their series of 111 patients. Compliance with bracing is an important characteristic in effectiveness. Twenty-three hours per day is necessary to achieve effective treatment.²⁸

The rationale for bracing and the benefit of school screening are factors in the treatment of scoliosis. The Milwaukee brace was developed in 1945 to provide a more efficient and comfortable passive correction and to aid sensation after operation for scoliosis secondary to polio.²⁹ It was not intended to be used as nonoperative treatment for spinal deformity. In 1954, however, it was applied as a conservative treatment for idiopathic scoliosis. An important part of bracing was the reduction of lumbar lordosis, which would secondarily induce active extension in the spine, thus reducing the deformity back to the sagittal plane.³⁰ No studies have demonstrated the reality of this concept. Lacking a clear rationale, the efficacy of bracing remains controversial.

In 1999, Dickson and Weinstein³¹ summarized the current state of affairs. "Despite the lack of data of treatment with a brace, bracing is still advocated."³¹ The authors also stated that "early detection breaks one of the pivotal promises that we can reliably

influence scoliosis favorably, and thus currently screening is unethical."

Muscle strengthening may be beneficial. Our observations were reinforced by the recent study of integrated electromyograms of thoracic and lumbar musculature of adolescent patients for scoliosis.³² This study found significant differences in lumbar myoelectric activity during isometric strength testing and standing extension during sudden axial overexertion. This was especially true of the lumbar muscles in a series of right thoracic curves. The authors note that differences were present although no deformity of the lumbar spine was noted in some patients, suggesting that asymmetrical spinal muscle activation may not be caused by the curvature itself, but may be more primary in the central nervous system.

Several limitations are present in this study. First, it is not a random, prospective, comparative study. Second, it consists of a small patient population. Third, patients were not followed for an extended period of time. Nonetheless, this study showed that muscle imbalance can be corrected by a specific exercise program that isolates the appropriate musculature, and progress could be measured and monitored. Compliance with this type of program, compared to wearing a brace, should not present a problem. Results of this treatment program are equal to or better than the results of bracing.

Two different types of equipment were used and had similar results. The failure of previous studies to demonstrate an efficacy of exercise is due to the fact that the amount of exercise and compliance was not measured. Moreover, no specific rationale for muscle training was noted. Side-to-side torsional strength difference offers a rationale to attempt correction.

Large, comparative studies of bracing versus specific resistance exercises are needed to document an effective nonoperative treatment program for adolescent idiopathic scoliosis.

REFERENCES

1. Lowe TG, Edgar M, Margulies JY, et al. Etiology of idiopathic scoliosis: current trends in research. *J Bone Joint Surg Am.* 2000; 82:1157-1168.
2. Nachemson A, Sahlstrand T. Etiologic factors in adolescent idiopathic scoliosis. *Spine.* 1977; 3:176-182.
3. Keessen W, Crowe A, Hearn M. Proprioceptive accuracy in idiopathic scoliosis. *Spine.* 1992; 17:149-155.
4. Fidler MW, Jowett RL. Muscle imbalance in the aetiology of scoliosis. *J Bone Joint Surg Br.* 1976; 58:200-201.
5. Green RJ. Histochemistry and ultrastructure of the paraspinal muscles in idiopathic scoliosis and in control subjects. *Med Lab Sci.* 1981; 38:197-216.
6. Khosla S, Tredwell SJ, Day B, Shinn SL, Ovalle WK Jr. An ultrastructural study of multifidus muscle in progressive idiopathic scoliosis. Changes resulting from a sarcolemmal defect at the myotendinous junction. *J Neurol Sci.* 1980; 46:13-31.
7. Spencer GS, Eccles MT. Spinal muscle in scoliosis, II: the proportion and size of type 1 and 2 skeletal muscle fibres measured using a computer-controlled microscope. *J Neurol Sci.* 1976; 30:143-154.
8. Yarom R, Robin GC. Studies on spinal and peripheral muscles from patients with scoliosis. *Spine.* 1979; 4:12-21.
9. Ford DM, Bagnall KM, McFadden KD, Greenhill BJ, Raso VJ. Paraspinal muscle imbalance in adolescent idiopathic scoliosis. *Spine.* 1984; 9:373-376.
10. Reuber M, Schultz A, McNeill T, Spencer D. Trunk muscle myoelectric activities in idiopathic scoliosis. *Spine.* 1983; 8:447-456.
11. Riddle HFV, Roaf R. Muscle imbalance in the causation of scoliosis. *Lancet.* 1955; 1:1245-1247.
12. Zetterberg C, Bjork R, Ortengren R, Andersson GB. Electromyography of the paravertebral muscles in idiopathic scoliosis. *Acta Orthop Scand.* 1984; 55:304-309.
13. Zuk T. The role of spinal and abdominal muscles in the pathogenesis of scoliosis. *J Bone Joint Surg Br.* 1962; 44:102-105.
14. Kennelly KP, Stokes MJ. Pattern of asymmetry of paraspinal muscle size in adolescent idiopathic scoliosis examined by real-time ultrasound imaging. A preliminary study. *Spine.* 1993; 18:913-917.
15. Stone B, Beckman C, Hall V, Guess V, Brooks HL. The effect of an exercise program on change in curve in adolescents with minimal idiopathic scoliosis. A preliminary study. *Phys Ther.* 1979; 59:759-763.
16. Sward L. The thoracolumbar spine in young elite athletes. Current concepts on the effects of physical training. *Sports Med.* 1992; 13:357-364.
17. Tanchev PI, Dzherov AD, Parushev AD, Dikov DM, Todorov MB. Scoliosis in rhythmic gymnasts. *Spine.* 2000; 25:1367-1372.
18. Becker TJ. Scoliosis in swimmers. *Clin Sports Med.* 1986; 5:149-158.
19. Mooney V, Gulick J, Pozos R. A preliminary report on the effect of measured strength training in adolescent idiopathic scoliosis. *J Spinal Disord.* 2000; 13:102-107.

20. Leggett S, Mooney V, Matheson LN, et al. Restorative exercise for clinical low back pain. A prospective two-center study with 1-year follow-up. *Spine*. 1999; 24:889-898.

21. Holmes B, Leggett S, Mooney V, Nichols J, Negri S, Hoeyberghs A. Comparison of female geriatric lumbar-extension strength: asymptotic versus chronic low back pain patients and their response to active rehabilitation. *J Spinal Disord*. 1996; 9:17-22.

22. Bobechko WP. Scoliosis spinal pacemakers [abstract]. *J Bone Joint Surg Am*. 1974; 56:442.

23. Bobechko WP, Hebert M, Friedman H. Electro-spinal instrumentation—current status. *Orthop Clin North Am*. 1979; 10:927-941.

24. Axelgaard J, Nordwall A, Brown JC. Correction of spinal curvatures by transcutaneous electrical muscle stimulation. *Spine*. 1983; 8:463-481.

25. Peterson LE, Nachemson AL. Prediction of progression of the curve in girls who have adolescent idiopathic scoliosis of moderate severity. Logistic regression analysis based on data from The Brace Study of the Scoliosis Research Society. *J Bone Joint Surg Am*. 1995; 77:823-827.

26. Lonstein JE, Winter RB. The Milwaukee brace for the treatment of adolescent idiopathic scoliosis. A review of one thousand and twenty patients. *J Bone Joint Surg Am*. 1994; 76:1207-1221.

27. Noonan KJ, Weinstein SL, Jacobson WC, Dolan LA. Use of the Milwaukee brace for progressive idiopathic scoliosis. *J Bone Joint Surg Am*. 1996; 78:557-567.

28. Ylikoski M, Peltonen J, Poussa M. Biological factors and predictability of bracing in adolescent idiopathic scoliosis. *J Pediatr Orthop*. 1989; 9:680-683.

29. Blount WP, Moe JH. *The Milwaukee Brace*. Baltimore, Md: Williams & Wilkins; 1973.

30. Dickson RA. Conservative treatment for idiopathic scoliosis. *J Bone Joint Surg Br*. 1985; 67:176-181.

31. Dickson RA, Weinstein SL. Bracing (and screening)—yes or no? *J Bone Joint Surg Br*. 1999; 81:193-198.

32. Avikainen VJ, Rezasoltani A, Kauhanen HA. Asymmetry of paraspinal EMG-time characteristics in idiopathic scoliosis. *J Spinal Disord*. 1999; 12:61-67.

program for antetorsional trunk muscles and showed it was effective in arresting progression in a small sample of patients with adolescent idiopathic scoliosis.

The machine used to strengthen the trunk muscles was similar to equipment used in many gyms. The same equipment had been used in a previous study to determine isometric strength differentials side-to-side in children with adolescent idiopathic scoliosis. Ten of the 12 participants had weaker muscles on the concave side of a thoracic curve. The study showed that the program of antetorsional exercises could correct these differences. The training needed to be carried out only twice a week to obtain a therapeutic effect. Compared to children treated in a brace, the compliance rate with their program was high.

In recent years, scant attention has been given to the role of muscle in the etiology or treatment of adolescent idiopathic scoliosis. Some previous studies have shown changes in the ultra structure of skeletal muscle in the trunk and distant sites, indicating a myopathic process. Myopathic muscle would probably not respond well to exercise.

Other studies have shown differences between the ratio of type I and type II muscle fiber on the concavity versus the convexity of the curve, indicating the changes may be secondary to the mechanical environment of the muscle. It would be interesting if further study could show whether the change in antetorsional strength exhibited by these patients was accompanied by changes in muscle fiber type, histochemical composition, or muscle bulk.

Although many physicians treating adolescent idiopathic scoliosis are dissatisfied with the efficacy of bracing, they will be cautious in incorporating this treatment into their practice. An enthusiasm for using computerized machines, such as the Isostation B-200 (Isotechnologies Inc, Hillsborough, NC) and Cybex (Cybex International Inc, Medway, Mass) for trunk muscle testing and rehabilitation, waned.

Putting these reservations aside, Mooney and Brigham pointed out that no previous study has looked at measuring torso rotation strength as a treatment for adolescent idiopathic scoliosis. The authors suggest a larger study should be undertaken to confirm or deny their findings. Although there are many difficulties in randomizing the treatment of adolescent idiopathic scoliosis, this should be done. It may be easier to randomize a study comparing this treatment as an adjunct to bracing, versus using a conventional brace alone.

These studies must carefully match these patients by curve magnitude and growth rate timed from the point of peak growth velocity. Results must be carefully compared against the known natural history of progression in adolescent idiopathic scoliosis. It would seem that the method, if effective, would work best with small curves in young patients, before the onset of Hueter-Volkman induced bony changes in the vertebral bodies.

The authors are to be congratulated for bringing to our attention a novel and interesting method for the treatment of adolescent idiopathic scoliosis, which will stimulate interest and research.

EDITORIAL COMMENT

ORTHOPEDICS: The study presented by Dr Mooney and Ms Brigham used a progressive resistive training